



Cambridge Health Alliance

# SilverStream® Wound Optimizing Rinse for the Treatment of Mildly Infected and Non-Progressing Diabetic Foot Ulcers and Venous Leg Ulcers



Adam Landsman, DPM, PhD, FACFAS

Chief, Division of Podiatric Surgery, Cambridge Health Alliance, and Harvard Medical School, Cambridge, MA

## ABSTRACT

This study represents the first prospective study for the treatment of mildly infected and non-progressive diabetic foot ulcers treated with SilverStream, a clear hypertonic solution that is composed of silver ions, menthol and surfactants.

Data from 44 wounds was examined to determine the change in overall appearance and condition following either daily or weekly treatment with SilverStream® over a period of 5 weeks.

Based on data collected at 8 independent sites, we found that the wounds demonstrated significant decreases in wound discharge, odor and the presence of necrotic or non-viable tissue. At the same time, wounds demonstrated a proportional increase in the percentage of granulation tissue. In fact, 21.5% of the wounds closed completely in 5 weeks or less, and the average decrease in wound size during the same period of time was 46%.

This preliminary data strongly supports the author's feeling that SilverStream will fill a unique niche in the treatment of DFU's by optimizing conditions necessary for these wounds to close.

## INTRODUCTION

SilverStream is a new wound irrigant specifically formulated to optimize conditions in difficult wounds. The primary ingredient of SilverStream, ionic silver, is used to reduce bacterial load and has been shown to help disrupt biofilms. The solution also contains menthol, which has been shown to enhance cellular migration, penetration into the cells, and adds a soothing sensation to wounds being treated. The combination of enhanced cellular migration and disruption of biofilm formation results in an overall optimization of the wound environment. Preliminary data has demonstrated that this sets the stage for the non progressive wound to begin the healing process.

SilverStream, by EnzySurge, Ltd., Israel, was cleared by the FDA in 2009 for the treatment of a variety of wounds including Diabetic foot ulcers, Venous leg ulcers, and other types of difficult, non-progressive wounds.



Fig. 1 SilverStream is currently available as a wound irrigant. It can also be used as part of a daily dressing protocol.

## HYPOTHESIS

We hypothesized that SilverStream would improve the condition of chronic diabetic foot ulcers, leading to increases in the presence of granulation tissue, reduced odor, and wound closure.

## MATERIALS AND METHODS

Clinicians from 8 independent wound care centers were asked to treat their most difficult wounds with SilverStream. Most clinicians asked the patients to wash the wound on either a daily or weekly basis. Photographs were taken at the beginning of treatment, and subsequently, on a weekly or bi-weekly basis. Wounds were evaluated subjectively to determine the following:

- Wound size (cm<sup>2</sup>) measured at baseline, 3 weeks, and 5 weeks.
- Presence of clinical signs of infection (baseline and 5 weeks)
- Percentage of granulation tissue covering the wound bed (baseline and 5 weeks)
- Percentage of non-viable tissue on the wound surface (baseline, 3 weeks, and 5 weeks)
- Physician perception of treatment (improved/worsened/unchanged)
- Patient perception of treatment (pain, discomfort, soothing, other)
- Adverse Events

Data from all 8 sites was pooled, resulting in a total of 44 evaluable wounds. Outcomes from this preliminary study are presented here.

## INCLUSION/EXCLUSION CRITERIA

Inclusion	Exclusion
<ul style="list-style-type: none"> <li>• Diabetic or Venous Stasis Ulcer</li> <li>• Wagner Grade 1 or 2</li> <li>• Tolerate off-loading w/ healing shoe, fixed ankle walker, or NWB</li> <li>• Age 18-70</li> <li>• IDDM or NIDDM</li> </ul>	<ul style="list-style-type: none"> <li>• Exposed Bone</li> <li>• Osteomyelitis assoc. w/ ulcer</li> <li>• Evidence of gangrene</li> </ul>

## RESULTS

An analysis was performed to examine the effects of SilverStream on diabetic foot ulcers and venous leg ulcers located in a variety of locations on the legs and feet. A total of 44 wounds were analyzed from 38 patients. Data was collected from 8 distinct clinical sites. Patients enrolled in this study were given adequate supply of the SilverStream wound irrigant, as needed according to their physicians treatment recommendations. Most patients applied the irrigant to their wound on either a daily basis or every other day. The average number of applications was 4.8 times per week. In addition, most applied a gauze dampened with the SilverStream solution to the foot as part of their bandage regimen. Ultimately, there was sufficient data to analyze 41 of the 44 wounds.

## RESULTS

In this study, the average wound measured 19.1cm<sup>2</sup> initially. Each wound was tracked and data was recorded after 3 weeks and 5 weeks of treatment. At 3 weeks, the average wound measured 17.9cm<sup>2</sup>, and by week 5, the average wound measured 14.9cm<sup>2</sup>. This data can be seen in Figure 2.

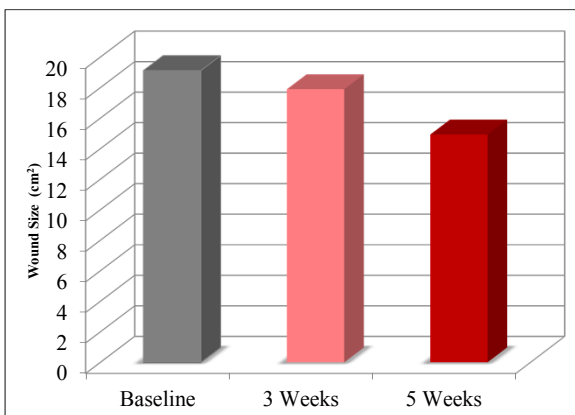
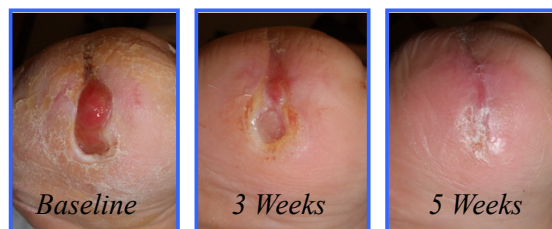

FIG. 2: Average wound size (cm<sup>2</sup>) at Baseline, and after 3 weeks and after 5 weeks.

A typical case showing reduction in size of a treated wound can be found in figure 3, below.

FIG. 3:



In this study, 92% of the wounds showed a measurable decrease in wound size during the 5 week period of observation. On average, the change in wound size was 46% reduction when compared to the initial area. Complete wound closure was achieved in 21.5% of the cases.

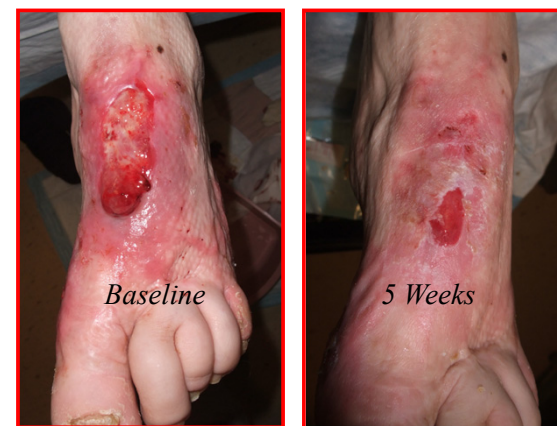Adverse events were virtually non-existent, with only one case reporting hypersensitivity to the silver (3.3%). 60.6% of the patients indicated that the solution created a soothing sensation, while 12% reported some level of discomfort during the irrigation and wound dressing process which or may not be attributable to the solution.

One key aspect of the SilverStream solution is its ability to reduce infection. In this study, 10 of the wounds initial showed some signs of infection, including odor, purulence, local erythema or cellulitis.

## RESULTS (CONTINUED)

Following treatment, 100% of the cases showed complete resolution of any signs of infection. Another critical element was the ability of SilverStream to aid in the development of granulation tissue, along with the removal of non-viable (necrotic or fibrous) areas. Overall, there was an average increase of 19% coverage in surface area with granulation tissue, and an average reduction of 9.4% of the wound area covered with fibrous and non-viable tissue. A typical clinical example of the development of granulation tissue and reduction in fibrous material can be seen in figure 4.

FIG. 4: The initial wound is covered with approximately 60% fibrous tissue, more proximally. After 5 weeks treatment with SilverStream, the wound shows a granular base, and no fibrotic or non-viable tissue.



## DISCUSSION

Based on the data from this pilot study, it has been demonstrated that SilverStream is very useful for normalizing difficult wounds. The combination of menthol, ionic silver, and surfactants in a hypertonic solution has resulted in a dramatic improvement in wounds that showed essentially no signs of progress.

In most cases, there was some combination of decreased wound size, decreased infection, development of new granulation tissue, and reduction of fibrotic tissue.

The mechanism by which these dramatic changes were brought about is due to a combination of interactions from the critical ingredients found in SilverStream. Ionic silver is widely regarded as an antimicrobial, and is well supported in the literature<sup>1</sup>. Furthermore, research seems to indicate that charged silver particles may prevent the adhesion of bacteria to surfaces where biofilms can form<sup>2</sup>. By preventing this initial adhesion, biofilms can not form.

SilverStream contributes to the debridement of the wound and helps to remove slough from the wound surface.

## CONCLUSIONS

This study has demonstrated that SilverStream can play a critical role in the treatment of diabetic foot ulcers and venous leg ulcers. It fills a unique niche, as a solution designed to enhance wound healing in chronic, non-progressive wounds.

The data presented here shows that the wounds treated with SilverStream increase in granulation tissue formation, decrease in the presence of non-viable tissue, and removal of biofilms as demonstrated by reduction in slough tissue on the surface of the wounds. In fact, 92% of the wounds showed a decrease in size, with an average reduction in wound size by 46% during the 5 weeks of observation.

Most patients found the solution soothing to use and this is attributed to the menthol component, which has a cooling and calming effect, as well as playing a role in combating odors, and helping to disrupt slough and biofilms.

The ionic silver component is known to be an effective antimicrobial, and in this study, we observed that 100% of the wounds that began with some sign of infection, achieved complete resolution by week 5.

Although SilverStream does help to close wounds, it's greatest attribute appears to be it's ability to normalize conditions within the wound bed, by reducing slough, increasing granulation tissue, controlling odor, and reducing bacteria load. The investigators observed clear improvement in the overall condition of wounds treated with SilverStream. We believe that it can be used as an excellent daily wound treatment or can be used to prepare the wound for more advanced biologic tissue grafts and skin substitutes.

## REFERENCES

1. Jude EB, Apelqvist J, Spraul M, Martini J; Silver Dressing Study Group. Prospective randomized controlled study of Hydrofiber dressing containing ionic silver or calcium alginate dressings in non-ischaemic diabetic foot ulcers. Diabet Med. 2007 Mar;24(3):280-8.
2. Jansen B, Kohnen W. Prevention of biofilm formation by polymer modification. J Ind Microbiol. 1995 Oct;15(4):391-6.

## ACKNOWLEDGEMENTS

We would like to thank doctors from the following medical centers who contributed patients to this study:

- Dr. R. Maloney, Beverly Hospital
- Dr. T Phillips and Dr. J. Powers, Boston Medical Center
- Dr. C. Milne, Bristol Hospital
- Division of Podiatric Surgery, Cambridge Health Alliance
- Clara Mass Hospital
- Hartford Hospital
- New England Sinai Hospital
- New York College of Podiatric Medicine